US EPA ARCHIVE DOCUMENT

DATE: September 13. 1979

E.P.A. Registration #: 7969-LG

SUBJECT: Ronilan; PP# 9F2205; Request for Permanent Tolerance of 10 PPM in or on Strawberries for Residues of the Fungicide, 3-(3,5-Dichlorophenyl)-5-Ethyl-5-Methyl-2,4-Oxazolidinedione and its Dichloroaniline - Containing Metabolites.

Caswell #: 323C
Accession #: 098254, 098253

Petitioner: BASF Wyandotte Corp
100 Cherry Hill Rd.
P.O. Box 181
Parsippany, N.J. 07054

FROM: William Dykstra
Toxicology Branch/HED TS-769 WHO 9/17/79 WSW

TO: 1. Henry Jacoby, (21)
RD, TS-767

2. RCB, TS-769

Recommendations:

1. The requested tolerance is not toxicologically supported. In order to further evaluate the toxicity of the pesticide, the following study is required:

   (a) 6-month dog feeding study

2. The proposed change in signal word and precautionary labeling from WARNING to CAUTION cannot be toxicologically supported for the formulated product.

3. Tha submitted eye irritation study is acceptable as core minimum data and shows irritation persisted in 2/6 at day 8.

4. Report C2; the summary of the macroscopic and microscopic examination results from the 3 months feeding trial on 40 beagles is acceptable as supplementary data and will be added to the original report of the 3 month dog study.

5. The following studies are currently lacking (in addition to recommendation #1) and considered desirable:

   (a) teratology - 2nd species
   (b) mutagenicity - multi-test evidence

187

A. Substance Identification

1. Chemical Name: 3-(3,5-dichlorophenyl-5-ethyl-5-methyl-2,4-Oxazolidinedione

2. Synonyms: Ronilan, Vinclozolin, BAS 352F, 83 258

3. Purity of Technical Material: 93%
Impurities:

[redacted]

4. STRUCTURE

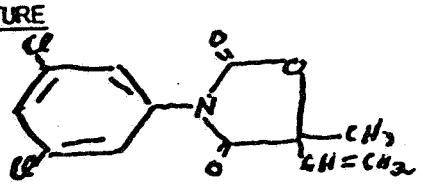

B. Referenced Petitions: PP# 8G2068

IMPURITY INFORMATION HAS BEEN DELETED.

7

C. Formulations: Ronilan Fungicide

INGREDIENT

Active Ingredient and Impurities

1. 3-(3,5-dichlorophenyl-5-ethyl-5-methyl-2,4-oxazolidinedione (vinclozolin) 50.00

[redacted]

INERT INGREDIENTS

[redacted]

100.00

Inerts cleared under 180.1001

IMPURITY/INERT INGREDIENT INFORMATION HAS BEEN DELETED.

REVIEW

A. Toxicology Studies

1. Prior Studies with references

a. Memo of 4/17/78 form R. Gessert; PP# 8G2068

1. Studies Conducted With Formulation

- 0 Rat acute oral LD_{50} > 16,000 mg/kg (both sexes)
- 0 Rabbit acute dermal LD_{50} > 2000 mg/kg (both sexes)
- 0 Rabbit primary eye irritation: score of 19.7; some corneal opacity and conjunctitivis, no iritis.
- 0 Rat acute inhalation LC_{50} > 1.17 mg/L for 4 hours
- 0 Rabbit primary skin irritation: P.I. = 2.75

2. Studies with Technical

- 0 Rat acute oral LD_{50} > 10,000 mg/kg (both sexes)
- 0 Rat acute dermal LD_{50} 2500 mg/kg (both sexes)
- 0 Rabbit primary skin irritation; P.I. = 1.3
- 0 Rabbit primary eye irritation; score of 1.89; no keratitis
- 0 90 Day Rat Feeding Study: NOEL = 450 ppm (highest dose)
- 0 90 Day Dog Feeding Study: NOEL = 300 ppm
- 0 Mouse Teratology: negative at 600 ppm
- 0 3-Generation Reproduction in rats: NOEL = 1458 ppm (highest dose)
- 0 Dominant Lethal Assay in mice: negative at 2000 mg/kg for five days.
- 0 Chronic Feeding/Oncogenic in rats for 130 weeks: Oncogenic Potential: negative; NOEL = 486 ppm.
- 0 Chronic Feeding/Oncogenic in mice for 26 months: Oncogenic potential: negative; NOEL = 1458 ppm
- 0 Metabolism: repeated oral dosing in rats

2. Submitted Studies

a. Report C1; Primary irritation of BAS 04 F to the eyes of White rabbits (BASF, ge-dd, March, 1978)

test mateial: BAS 352 04 F

0.1 ml of test material was instilled into the right eye of 6 white Vienna Rabbits with the untreated eye serving as a control. Observation and scoring at 24, 48, 72 hours and 8 days.

Results: No corneal opacity in any of the six treated eyes. No iritis but conjunctivitis in 6/6 at 24 hours which remained in 2/6 at day 8; score of 3.0

Classification: Core minimum DATA TOX CATEGORY II: WARNING eye irritation lasted up to day 8 in 2/6 rabbits.

b. Report C2; Summary of the macroscopic and microscopic examination results from the 3-month feedin trial on 40 Beagles (Professor Klaus-jeachim Hempel, Pathological Institute, General Hospital Heidberg; May 2, 1975)

A macroscopic and microscopic examination was carried out on the organs of a total of 40 beagles (20 male and 20 female animals), obtained from the post-mortem examination after a 91-94 day trial period, with a fine-tissue examination of the following organs; hearts, aorta, lungs, trachea, thyroid gland, esophagus, stomach, de odenum, small intestine, ileocaecal valve, large intestine, rectum, mesenterial lymph glands, liver, gall bladder, pancreas, spleen, kidneys, adrenal glands, urinary bladder, testicles, ovaries, brain, hypophysis, and eyeball with lens (bilateral). This examination, which was carried out separately for the different groups (control group and 4 trial groups, revealed in the first place a few tissue changes which were clearly attributable to the conditions of death (agonal origin). These changes included spots of hyperaemia in the individual organs, especially the brain and spleen. An edemotous loosing of the brain substance, a pulmonary edema, hemorrhages in the brain, in the soft meninges, in the lungs and spleen were also observed. An atelectasis (respiration confined to individual points) and a vesicular pulmonary emmphysema (vesicular distension of the lung tissue) should also be included in this category. The formalin-fixed material received careful macroscopic and microscopic examination preparation and was embedded in paraffin. The histological sections were evaluated after straining with hematoxylin-eosin, frozen sections being prepared in addition to the liver, the two kidneys, and the two adrenal glands, using a fat reaction.

5

Trial Group 0 (0 ppm)

In one male and two female animals of the control group, granulomatous inflammatory foci were found in the lungs plus a clearly apparent acute vesicular emphysema. The granulomatous of inflammation was a parasitic infestation (ascaridae) which affected many of the trial animals. A finding which deserves to be mentioned was a visible lipid content in the renal tubules in four male and two female dogs which would be easily revealed by staining. In a further two male and one female dog this change was just indicated.

Trial Group 1 (100 ppm)

Two male and three female dogs exhibited granulomatous - inflammatory foci in the lungs against the background of a parasitic infestation or after aspiration. In two male and female animals a very slight powdery fat phanerosis was recognizable which could be revealed in the epithelium of the liver by staining. In one male and two female dogs granulomatous - inflammatory foci were found in both kidneys and once again lipid deposits in the renal tabules (three male and four female animals). In two female animals the bile was present in the bile capillaries in the form of very small droplets. No liver cell icterus was present. This was clearly a variation from the norm which appeared clearly under staining. An adenoma of the adrenal cortex was found in one male dog.

Trial Groups 2 (300 ppm)

In one male and two female dogs granulomatous inflammatory changes were found in the lungs and, in addition, in two female animals in the kidneys. A slight powdery fat phanerosis was found in the liver cells in one male and one female animal. All the animals of this trial group 2 exhibited an increased lipid content in the renal tubules.

Histological examination revealed the presence of bile in the form of tiny droplets in the smallest bile capillaries in two female dogs. There were traces of a similar finding in two male animals also. As in Trial Group 1, this histological finding may be regarded as within the normal range of variation. A slight clouding (no opacity) was found in the left eye of one male dog.

Trial Group 3 (1000 ppm)

Granulomatous-inflammtory changes were found in the lungs of one male dog. Two male animals exhibited a slight fatty degeneration of the liver epithelia and one female animal an inflammatory granuloma in the renal parenchyma. In addition, fatty deposits were found in the renal tubules in three male and four female dogs. In two male and two female dogs of this trial group, a cholestasis was present in the liver with bile thrombi and small bile cylinders.

6

Trial Group 4 (2000 ppm)

Inflammatory granuloma formations were found in the lungs of one male and two female dogs. Three male and one female animal had powdery fatty deposits in the parenchyma of the liver and lipid deposits were found in the epithelium of the renal tubules in three male and three female dogs. All animals displayed a moderate cholestatis in the parenchyma of the liver. No occurrence of liver cell icterus was observed.

Conclusion:

In trial group 3 (1000 ppm) two male and two female animals were suffering from a cholestasia in the liver. In trial group 4(2000 ppm) all animals were suffering from a clearly marked cholestasis in the liver. No accompanying changes in the liver cells or reticulo-endothelial system could be found.

The cholestasis of the kidney is a dose-dependent response to treatment in the 1000 ppm and 2000 ppm groups. The remaining pathological - anatomical findings were not considered related to the administration of test compound.

Classification: Supplementary DATA to be added to 3-month dog study.

9